

## Dactylogyrids (Dactylogyridae: Monogenea) on Common Carp (*Cyprinus carpio* L.) in Freshwaters of Iran and Description of the Pathogenicity of *D. sahuensis*

B. Jalali<sup>1\*</sup> and M. Barzegar<sup>2</sup>

### ABSTRACT

Common carp is infected by five *Dactylogyrus* spp in both pond and natural lake habitats in Iran, namely *D. extensus*, *D. anchoratus*, *D. achmerovi*, *D. vastator* and *D. sahuensis*. Fry and fingerlings are more sensitive to infection and their sensitivity is increased with the higher density of fishes usually found in ponds. General gill lesions in dactylogyrosis are quite similar but there are few differences in local lesions among *Dactylogyrus* spp infecting common carp. In this paper, the geographical distribution of *Dactylogyrus* spp of common carp is presented and the gill histopathology caused by *D. sahuensis* is described and discussed.

**Keywords:** Common carp, *Dactylogyrus* spp, Gill histopathology, Iran.

### INTRODUCTION

Common carp occur naturally in the Caspian sea basin and the Tedzhen River, but are also cultivated. The farming of common carp started in Iran at least 40 years ago in ponds situated in the north of the country, but now the fish species has been widely transplanted to different regions of the country for farming purposes, both in fish ponds and natural lakes [4]. During the period of rearing, the common carp is infected by many parasites, either within their direct life cycle (Monogenea and most Protozoa) or their indirect life cycle (Digenea and Cestoda). During this investigation into monogenean parasites on freshwater fishes of Iran, common carp was found to be infected by five *Dactylogyrus* species, some of which are highly pathogenic, especially for fry and fingerlings cultured in

ponds. In the present paper, the distribution of Dactylogyrids infecting common carp in Iran are introduced and the pathogenicity of *D. sahuensis* is compared with the other Dactylogyrids of common carp and is discussed for the first time.

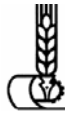### MATERIALS AND METHODS

The present research work was started in 1990 [6] and continued till 2002 [10]. Altogether, 250 specimens of common carp of various sizes and of different ages were collected in different localities from fish ponds, hatcheries and natural lakes in Iran and also from the southern part of Caspian Sea where they were caught along with Caspian frisian roach and other cyprinids by gill net and beach seine. Parasites were collected under a microscope at a magnification of x 60-100. Monogeneans were picked up live by a pipette from the scraping, placed under a cov-

<sup>1</sup> Veterinary Department, Science and Research Branch, Islamic Azad University, P. O. Box: 14515-775. Tehran, Islamic Republic of Iran.

<sup>2</sup> Abzigostar Consulting Engineering Company, P. O. Box: 17445-151, Tehran, Islamic Republic of Iran.

\* Corresponding author.



erslip and fixed in an ammonium picrate solution according to Gussev's method [5]. Histological studies were performed only on the gills of common carp damaged by *D. sahuensis*. The majority of samples were collected from pond farms and the rest were obtained from laboratory stock. During examination, the fish gills were divided into two parts, one half was examined in an untreated state for gross and microscopic lesions and the other half was fixed immediately in 10 % formalin for histopathological processing. The fixing solution was diluted to 4 % after 4 to 24 hours, washed for 24 hours and dehydrated in graded ethanol. Samples were sectioned parallel to their longitudinal axis. A few sections were cut in the plane of the lamella or transversally. The methods used for histological examination are based on Roberts [16].

## RESULTS

The results of the present papers are given in Tables 1 and 2.

Five *Dactylogyrus* spp. (*D. extensus*, *D. anchoratus*, *D. vastator*, *D. achmerovi* and *D. sahuensis*) infect common carp in both pond culture and natural lakes [1, 2 and 6]. Among them, *D. extensus* was the most prevalent in adult fish (18-29cm) and *D. vastator* and *D. anchoratus* in fingerlings (3-8 cm) [3, 6, 7, 8, 9 and 10]. Apparently, there is a tolerance of *D. extensus* to salinity and water temperature fluctuation, which enable it to exist in different habitats, while the sensitivity of *D. vastator* Prevents it from being highly prevalent. Furthermore, *D. achmerovi* was found in the gills of common carp in Anzali lagoon [1]. The survey on *Dactylogyrus* spp in the gills of adult fish in the Caspian Sea brackish water shows that *D. extensus* was the only species found in the gills of adult fish in the Caspian Sea

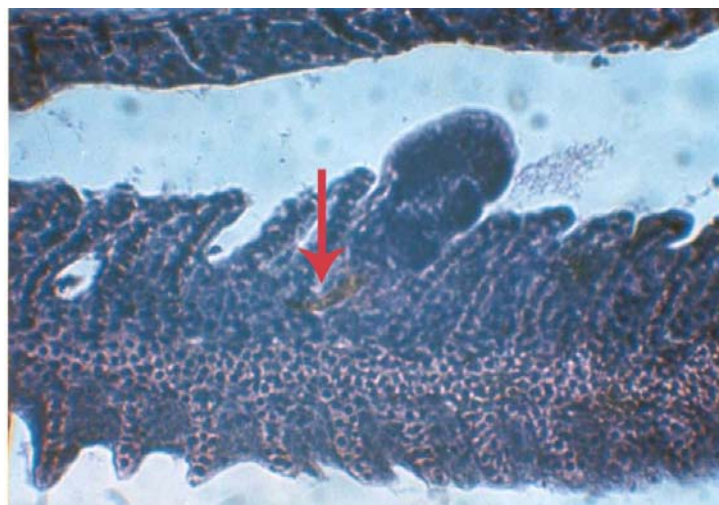
**Table 1.** Known *Dactylogyrus* spp found in cultured common carp in Iran.

<i>Dactylogyrus</i> spp	Guilan (Sangar)	Mazandaran (Sameskandeh)	Esfahan (Lavark and Karaskan)	Guilan (Anzali lagoon) <sup>a</sup>	Khozestan (Shahid Maleki)	Tehran
<i>D. achmerovi</i> Gussev, 1955						
<i>D. anchoratus</i> Dujardin, 1845	+	+	+	+	+	
<i>D. extensus</i> Mueller et Van Cleave, 1932	+	+	+	+	+	
<i>D. sahuensis</i> Ling, 1965		+				
<i>D. vastator</i> Nybelin, 1924	+			+		+

<sup>a</sup> Pen culture

**Table 2.** Known *Dactylogyrus* spp found in common carp in natural waters of Iran.

<i>Dactylogyrus</i> spp	Caspian sea	Kordestan (Zarivar lake)	Sistan (Hamoon lake)	Guilan (Anzali lagoon)	Fars (Kaftar lake)	Esfahan (Zayandehrood river)
<i>D. achmerovi</i> Gussev, 1955				+		
<i>D. anchoratus</i> Dujardin, 1845			+	+	+	
<i>D. extensus</i> Mueller et Van Cleave, 1932	+	+	+		+	+
<i>D. sahuensis</i> Ling, 1965						
<i>D. vastator</i> Nybelin, 1924			+	+		

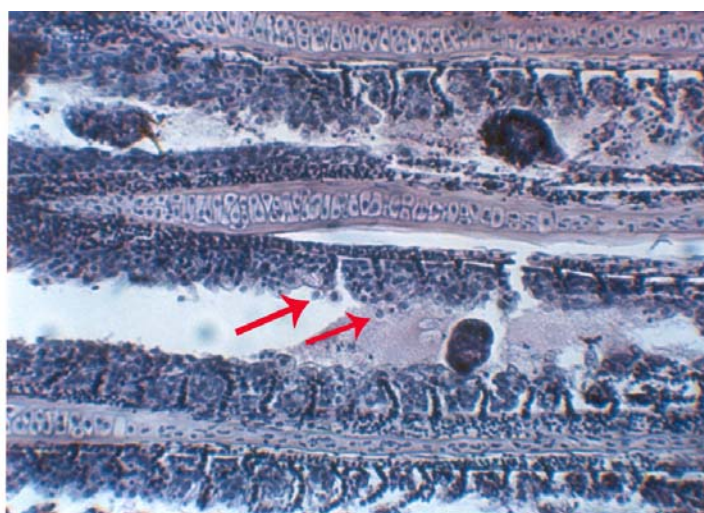


**Figure 1.** Attachment of *D. sahuensis* to the gill filaments. Anchors are pierced into the basis of the secondary lamellae. Histological section. H. and E. x400.

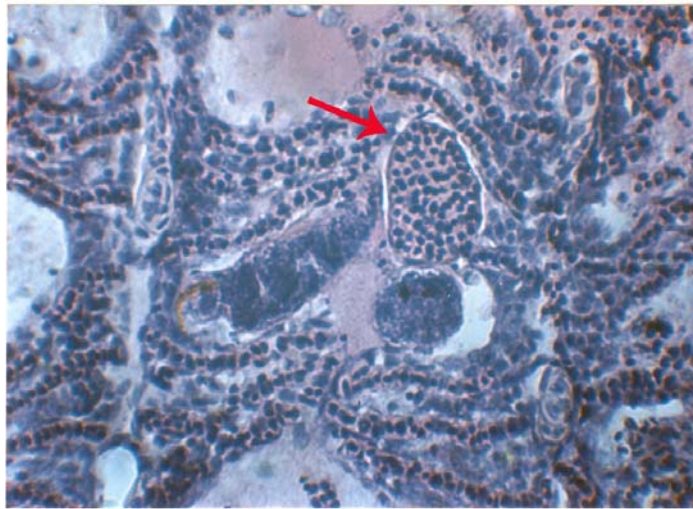
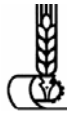ecosystem [9]. Despite frequent infections with the above monogeneans, no pathological changes were observed on naturally occurring, fresh-water infected fishes. Cultured fish, especially fingerlings, however, often showed disease symptoms and alterations in the gill filaments. Among them, the diseases of common carp caused by *D. extensus* and *D. vastator* correspond to these

symptoms, which were described by Papperna [14] and Prost [15]. Similarly, alterations caused by *D. lamellatus* on the gills of the grass carp resembled the ones detailed by Molnar [11].

Besides these cases, there is record of a serious infection caused by *D. sahuensis* with severe pathological changes appearing on the gills of the common carp. The present



**Figure 2.** Degeneration in the gills of common carp due to *D. sahuensis* infection. See the desquamated cells around worms and free sera between lamellae. histological section. H. and E. x200.

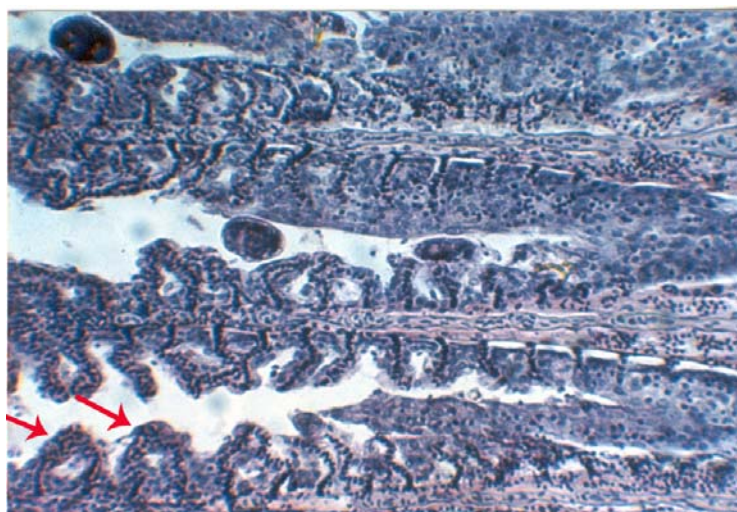


**Figure 3.** *D. sahuensis* piercing its anchor into lamellae. Close to the worm telangiectasia of the capillary of the lamellae is seen. Histological section. H. and E. x400.

survey shows that *D. sahuensis* infection is not very common in Iranian fishponds. In most cases this infection occurs without disease symptoms. In experimental conditions however, *D. sahuensis* infection evoked serious pathological changes on the gills of the fingerlings.

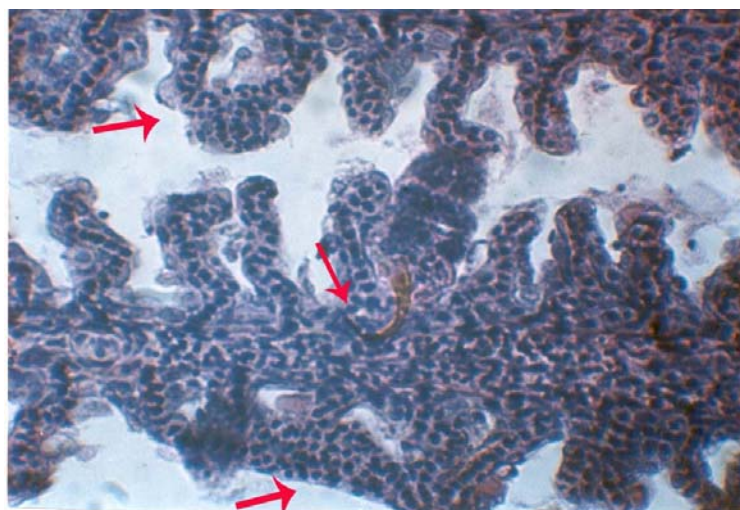
While raising fingerlings of common carp of 3-5 cm for experimental purposes, the disease occurred and losses appeared in the

aquarium. After dissecting the fish, serious infection of gill by *D. sahuensis* was found in every case. The hemibranches of the gills of the affected fish harbored 40 to 300 specimens of *D. sahuensis* each. In one case the monogenean infection was accompanied by *chilodonella* infection as well. In gross examination, the gills were pale and anaemic, covered by thick mucus. Worms were also found attached to the filaments, initially



**Figure 4.** Proliferation epithelium grows over the gill lamellae due to *D. sahuensis* infection. Histological section. H. and E. x200.



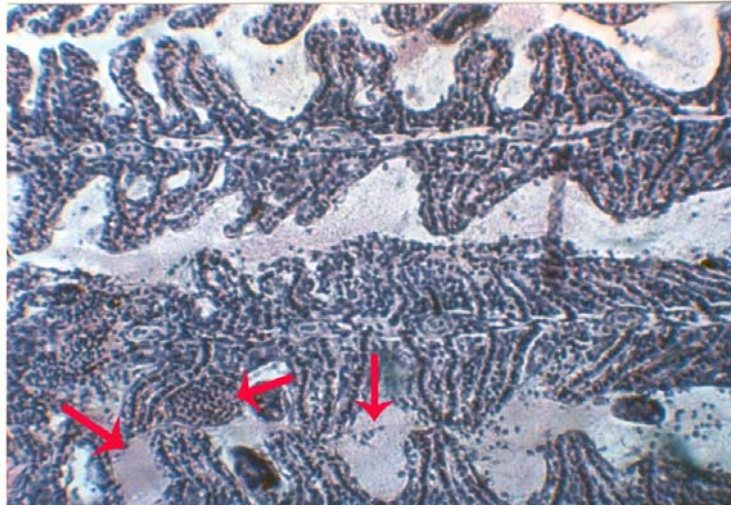


**Figure 5.** At the attachment of the *D. sahuensis* deep holes are formed due to degeneration of the lamellae 3 to 5 lamellae grows together. Histological section. H. and E. x400.

in the middle region. Fish infected only with a moderate number of *D. sahuensis* (30-50 specimens in one fish) showed histological changes only at the attaching points of opisthaptor (Figure 1). At this site the parasite was located between two neighboring secondary lamella, boring their anchors into the basally located multilayered epithelium. In most cases anchors were fixed only in the epithelium (Figure 2). In other cases, however, they reached the propria layer and the connective tissue covering the cartilaginous gill rays of the primary filaments. Among the general changes in these cases, only a moderate proliferation of the epithelium between secondary lamella was recorded. In heavy infections, over 100 specimens of *D. sahuensis* were found in the gills of infected fish and local and general lesions were also found in the gills. Local lesions were similar to the mild infections and they were characterized by deep holes at the parasites point of attack. At these sites (Figure 3, 4, 5 and 6), the multilayered epithelium covering the primary filaments became thin in great contrast with the space between the neighboring lamella, which was filled with proliferating

cells. General gill lesions were comprised of degenerative tissue defects, hemorrhages, necrosis, atrophy and cell proliferation, but the appearance of these symptoms was different in all cases.

In less severe cases the degenerative changes were dominant. The epithelium of the secondary lamella were damaged, degenerated and underwent cytoplasmic disintegration and karyolysis. In more severe cases, degeneration and proliferation were seen at the same time. Degeneration was characterized by the disintegration of the superficial epithelium cells, which lost their normal appearance, both nucleus and the cytoplasm became swollen and they underwent aryolytic degeneration (Figures 2 and 3). Proliferative changes appeared in the proliferation of the multilayered epithelium between filaments, and the epithelium grew over the level of the secondary lamella, forming lamellae processes comprising 3 to 6 (Figures 3, 5 and 6) or in rare cases covering a large part of the primary filament (Figure 4). In the latter case, a proliferative epithelial tissue composed of cells with swollen nuclei and disintegrated plasma



**Figure 6.** Due to *D. sahuensis* infection the gills are covered by copious mucus and extravasacular red blood cells. Telangiectasia of the damaged capillaries is common. Histological section. H. and E. x200.

covered the remnant or capillaries of the primary lamellae (Figure 4). At the damaged end of the secondary lamella, telangiectasia of the capillaries developed (Figures 3 and 6). Inside the copious mucus covering the filament, extravascular red blood cells were found. At the attachment sites where the parasites fixed themselves to the gill filaments, characteristic depressions were formed in which the haptor of the parasite and the hooks were recovered (Figures 5 and 6). The tip of the anchors reached the propria layer and often damaged the capillaries at the basis of the lamellae. Hooks, however, pierced only into the epithelial cells, causing damage to the superficial cells.

## DISCUSSION

The gross and microscopic lesions caused by *D. sahuensis* resemble the damage done by *D. vastator* and *D. lamellatus* in many respects, but there are significant differences as well. Local degeneration seemed to be caused by the attachment and feeding of *D. sahuensis* and is most intensive around the attachment site of the parasites. Hemor-

rhages and formations of depressions in filaments seem to be due to the mechanical damage of the anchors and hooks, while the proliferation of the multilayered epithelium is assumed to be caused by the feeding mechanism of these parasites. On the basis of histopathological findings, it is suggested that *D. sahuensis* can occasionally become a similar pathogen to carp fingerlings as the better studied common carp monogeneans such as *D. vastator* or *D. extensus*. In the case of *Dactylogyrus vastator*, Wunder [17] and Paperna [13] described clubbing of primary filaments which means the formation of primary filaments and the loss of secondary lamellae. Molnar [11 and 12] who studied *D. lamellatus* infection in grass carp and *Ancyrodiscoides vistulensis* infection of the European catfish, found a similar phenomena. This author described also the adhesion of the primary filaments, which resulted in the formation of thick clubs. Prost [15] found neither adhesion nor clubbing of the filaments with *D. extensus* and *D. anchoratus* infections in the common carp. She described local proliferations on the affected parts of the filaments. In *D. sahuensis* infection, no adhesion of the fila-

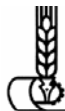ments were observed and the symptoms are more in accordance with changes described by Prost [15] for *D. extensus*. However, a specific alteration only for *D. sahuensis* infection was recorded, which was characterized by the adhesion of some neighboring secondary lamellae.

#### ACKNOWLEDGMENT

The authors are most thankful to Dr. K. Molnar, the well-known Hungarian fish parasitologist, for his excellent assistance in the description of pathological changes of common carp infected with *Dactylogyrus sahuensis*.

#### REFERENCES

1. Abolghasemi, S. G. 2000. Identification of Monogenean Parasites of Fishes in Sefidrood River and Introduction of New Genus and Species in Iran (in Persian). *Iran. J. Vet. Res.*, (University of Shiraz). **3(2)**: 118-130
2. Asadzadeh, M. A., Mokhayer, B. and Jalali, B. 2000. Health Assessment of External Parasites of Cultured Cyprinidae in Pen Culture of Anzali Lagoon (In Persian). *Pazoo-hesh Sazandegi*, **47**: 97-102.
3. Barzegar, M. and Jalali, B. 2002. Parasites of Kaftar Lake Fish, their Distribution and Economical Importance (In Persian), *J. Sch. Vet. Med.*. (Shahid Chamran University, Ahwaz) **5**: 52-64.
4. Coad, W. and Abdoli, A. 1993. Exotic Fish Species in the Freshwaters of Iran. *J. Zool. Middle East*, **9**: 65- 80.
5. Gussev, A. V. 1983. The Method of the Collection and Processing of Fish Patristic Monogenean Material (In Russian). *Nauka*, Leningrad, 48 p.p.
6. Jalali, B. and Molnar, K. 1990 b. Occurrence of Monogeneans Freshwater Fishes of Iran II: *Dactylogyrus* spp on Cultured Iranian fishes. *Acta. Vet. Hung.*, **38 (4)**: 239- 242.
7. Jalali, B. 1994. Monogenean Parasites of Freshwater Fishes in Iran (Ph. D. thesis). Prepared in the Veterinary Medicine Research Institute, Hungarian Academy of Science, Budapest, Hungary, 195 pp.
8. Jalali, B. 1997. Parasite and Parasitic Diseases of Freshwater Fishes of Iran. (In Persian) Fisheries Company of Iran Publication, 564 pp.
9. Jalali, B. and Vatandoost, F. 1997. Some of Parasites of Caspian Sea fishes (In Persian). Fisheries Company of Iran Publication. 18 pp.
10. Jalali, B., Barzegar, M. and Sohrabi, H. A. 2002. Preliminary Survey on the Parasites of Some Fishes in Zarivar Lake (In Persian). *Iran. J. Mar. Sci.*, **1 (2)**: 27-40.
11. Molnar, K. 1972. Studies on Gill Parasitosis of the Grass Carp (*Ctenopharyngodon idella*) Causes by *D. lamellatus* Achmerov 1952, IV: Histopathological Changes. *Acta. Vet. Acad. Sci. Hung.* **22 (1)**: 9-24.
12. Molnar, K. 1980. A Histological Study on Ancyrodiscooidosis in the Sheatfish (*Silurus glanis*) *Helmintologia*, (**17**): 117- 126.
13. Paperna, I. 1963 a. Dynamic of *D. vastator* Nybelin, 1924 (Monogenea) Population on the Gill of Carp Fries in Fishpond. *Bamidgeh*, **15 (4/9)**: 31-50.
14. Paperna, I. 1964 b. Host Reaction to Infestation of Carp with *D. vastator* Nybelin, 1924 (Monogenea). *Bamidgeh.*, **16 (4)**: 129-141.
15. Prost, M. 1963. Investigation on the Development and Pathogenicity of *D. anchoratus* (Dujardin, 1845) and *D. extensus* (Mueller et Van Cleave, 1932) for Breeding Carp. *Acta. Parasitol. Polon*, **11 (2)**: 17- 48.
16. Roberts, R. J. 2001. *Fish Pathology.*. Bailliere. Tindall. England. 477 pp.
17. Wunder, W. 1926. *Dactylogyrus vastator* Nybelin aus dem der Karpfenbrut, Ein Beitrag zu dem Beziehungen parasite Mud wirstier. *Biol Zenthl.*, **4 b (12)**: 748- 755.



## گونه‌های جنس *داکتیلوژیروس* ماهی کپور معمولی در ایران و بیماری زایی *داکتیلوژیروس* *ساهونزیس*

ب. جلای و م. برزگر

### چکیده

ماهی کپور معمولی در استخرهای پرورشی و نیز دریاچه‌های طبیعی بوسیله گونه انگل مونوژن شامل *داکتیلوژیروس اکستنسوس*، *داکتیلوژیروس آنکوراتوس*، *داکتیلوژیروس اخمرووی*، *داکتیلوژیروس واستاتور* و *داکتیلوژیروس ساهونزیس* آلوده می‌شوند. بچه ماهیان نارس و انگشت قد حساسیت بیشتری به این عفونت داشته و این حساسیت با افزایش تراکم در استخرها بالا می‌رود. آسیب‌های عمومی در آبشش ناشی از گونه‌های مختلف *داکتیلوژیروس* مشابه است، اما در ارتباط با آسیب‌های موضعی تفاوت‌های اندکی بسته به گونه انگل در آبشش دیده می‌شود. در این مقاله آسیب‌شناسی سلولی و بافتی ناشی از *داکتیلوژیروس ساهونزیس* برای اولین بار تفسیر شده و در مورد آن بحث می‌گردد.